



Light and Scanning Electron Microscopic Studies on *Caligus spp. in Mugilid fish*

Ismail A. M. Eissa ¹,
Mona M. Ismail ¹,
Fatma Alzahraa R. A.
M. El Hadedy ¹, Eman
M. Abou elhassan* ²

¹Department of Veterinary
Fish Diseases and
Management, Suez Canal
University, Ismailia
41522, Egypt.

²Department of Veterinary
Parasitology, Suez Canal
University.

*Corresponding author.
Eman M. Abouelhassan
Tel.: +201016864524
E-mail address:
hassanem@yahoo.com

Abstract:

This study was conducted on 224 marine fish belong muglid species namely; *Mugil cephalus*, *M. capitus*, and *M. seheli* randomly collected from fish farms during the year 2015 in Damietta Governorate, Egypt. Most of the clinical signs of these fishes were recorded. The clinical examination revealed hemorrhagic spots in the areas of the head, abdomen, tail, around the mouth, and anus. Some of fishes showed paleness in gills and showed a mosaic appearance on the gills. The percentage of *Caligus sp.* was recorded in *M. cephalus* (7.94%) , (11.65%) in *M. capitus* and (0%) in *M. seheli*. Seasonal prevalence and Light and Scanning Electron Microscopic identification have been carried out.

Key words: Light, Microscopic , *Calligus spp, Mugilidae*

Introduction

Fish is considered one of the most valuable sources of protein food and an effective solution for world nutritive problems and deficiency in the future. Mugilid Fish are economically significant and are important food fishes, because of their simple diet as well as their rapid growth, have made them the object of aquaculture in many parts of the world (Oren, 1981). Mulletts have worldwide distribution and inhabit tropical and temperate seas; a few spend their lives in freshwater (Nelson, 2006).

Parasites have recently been highlighted as serious pathogenic problems in cultured mullet fish in marine and brackish water (Noor El-Deen et al., 2012), and therefore a threat to the developing industry of finfish mariculture (Ruckert et al., 2008).

Parasites have recently been highlighted as serious pathogenic problems in cultured mullet fish in marine and brackish water (Noor El-Deen et al., 2012). Therefore, a threat to the developing industry of finfish mariculture (Rucker et al., 2008), one of these parasites is *Caligus sp.* causing loss of appetite, fish become debilitated with extensive mucus, rubbing against hard objects, nervous and respiratory manifestations (Noor El-Deen et al., 2012).

Materials and Methods

Fish:-

A total number of 224 alive fish (63 *Mugil cephalus* , 103 *Mugil capitus* and 58 *Mugil seheli*) of different body weights were randomly collected alive from private fish farms in Damietta Governorate, Egypt during

the period from January 2015 to December 2016. Fish samples were submitted to clinical, postmortem, and parasitological examinations.

Study area:-

Fish were collected from semi-cultured private farms in Damietta Governorate, Egypt. The collected fish were transported alive as soon as possible in tanks containing pond water.

- **Determination of fish body weight and total length:-**

The body weight and total length of each examined fish were determined separately before dissecting to avoid any fluid or tissue losses using an electronic balance.

- **Clinical examination:-**

Alive fish in the well-prepared glass aquaria were clinically examined, for detection of any macroscopic lesions according to Conroy and Herman (1981).

- **Postmortem examination:-**

The fish specimens were subjected to postmortem examination for the detection of any internal abnormalities. They were placed on the lateral side and a longitudinal incision was made along the ventral midline from the anal opening to just ventral to the gill chamber and extends from the posterior peritoneal cavity into the pericardial sac. Another incision at both ends of the previous incision was made and extended to the dorsal aspect of the body cavity. The body wall was dorsally reflected exposing the viscera to identify and examine the intestine, liver, spleen, gonads, and heart (Noga, 1996).

- **Parasitological examination:-**

The fish specimens were examined macroscopically and microscopically for external and internal parasites after they were sacrificed.

- **Examination of skin and fins:-**

Skin and fins of freshly sacrificed fishes were examined with naked eye and magnified lens for searching about external parasites. They were placed on

dissecting dish, scraped with a scalped blade from just behind operculum to the tip of tail, fins, and scales and mucus were transferred to slides with a drop of distilled water and cover slip to prevent drying and examined microscopically.

- Examination of gills:-

The operculum was removed with scissors, then the gills were exposed, removed and dissected separately and examined with naked eye and magnified lens to detect the presence of any parasites.

For microscopical examination, the gill arches were removed to a slide and proceed to cut away the cartilaginous arch using needles to separate gill lamellae, few drop of water or physiological saline were added on the slide to ensure a uniform distribution of the filaments under the entire cover slip (Lucky, 1977).

Examination of gill mucus by transfer to slides with a drop of distilled water and examined under microscope to detect the parasites.

The detected crustacean were collected in a test tube, washing and cleaned by distilled water. They were fixed in 3% formalin and preserved in equal amount of 70% alcohol – 5% glycerin in test tube. Permanent amount were prepared by passage in descending grades of alcohol (70, 50, and 30%), cleared in glycerin and mounted in glycerin – gelatin, according to Lucky (1977).

Scanning Electron Microscopy (SEM) (Kua and Halmi, 2010):

Specimens for SEM were first hydrated from 70% ethanol to fresh water. The Caligids were washed, samples were fixed in McDowell-trump fixative prepared in 0.1m phosphate buffer, PH 7.2 at 4C for 24 hours. Next, it was postfixed in 1% Osmium tetroxide prepared in the same buffer as above at room temperature

for 2 hours. After that, specimens were washed twice with distilled water. The sample was dehydrated with 50%, 75% , 95% and 100%ethanol. The dehydrated tissue was immersed in 2ml of hexamethyl disilazane for 10 minutes. The hexamethyldisilazane is then decanted from the specimen vial and left in the desiccators to air dry at room temperature. Then, the dried specimen was mounted on to SEM specimen stub with double-sided sticky tape. It was coated with gold before been viewed under Leo Supra 50 vp Field emission SEM equipped with Oxford INCA 400 energy dispersive x-ray microanalysis system at magnifications of 27x- 1.27KX (Atteya et al.,2019).

Results

The examination performed on the freshly dead fishes were revealed the followings:

Gills of affected fishes showed a marbling (mosaic) appearance (areas of congestion and paleness) (Fig. 1A), Microscopically inflammation of gills were observed (Fig. 1B). Gill tips were stocked with grayish coloration and excessive mucous secretion. Detached filaments and sever anemic appearance was seen in gills of some fishes. Gill congestion and inflammations were also noticed.

Morphological description of the *Caligus spp.* by light microscope microscope.

Adult parasite is light yellow or creamy in color and are sexually dimorphic. The bodies are flattened, elongated or spherical with brown spotted coloration. They have a quadrilateral cephalothorax covered by large dorsal and hard shield fringed with margins membrane like inverted saucer. The postero-lateral margins distinctly lobate with one to three-segmented abdomen. There are two eyes at the anterior edge. (Fig2).

Morphological description of the *Caligus* spp. by scanning electron microscope

Scanning microscopic examination for the samples revealed the most characteristic features. Lunules, first and second antennae are clearly visible. Ventrally, all appendages are situated; the post-antennal process strongly recurved and has a tiny claw. The antenna has three-segments, with the last segment being the smallest and armed with setae. The proximal segment is thin and unarmed. On the medial margin of the distal blade of the mouth tube, the mandible and maxilla have a lot of teeth. Maxillipeds are three-segmented, with the middle and distal segments joining to create a subchela with a pointed claw. The proximal segment is robust but unarmed. The base of the sternal furca is triangular, narrow, and splits (Fig3 and 4).

Prevalence of *Caligus* spp. infestation among the examined fishes:

The total infestation among the examined fishes was (7.59%). It was (7.94%) in *Mugil cephalus*, (11.65%) in *M. capitus* and (0%) in *M. seheli* (Table 1).

Discussion

The parasitological characteristics of *Caligus* spp. that are characterized by the adult parasites are light yellow or creamy and are sexually dimorphic. The bodies are flattened, elongated, or spherical with brown spotted coloration (Helna et al. 2018). They have a quadrilateral cephalothorax covered by a large dorsal and hard shield fringed with margins membrane-like inverted saucer. The postero-lateral margins are distinctly lobate with one to three segmented abdomen. There

are two eyes at the anterior edge. Females have two characterized long bar-shaped egg pouches or strings (Abdel-Gaber, R. et al. 2020)

Most characteristic features are clearly observed by the electron microscope (Mahdy and Abu El Ez, 2016).

Regarding the seasonal prevalence of crustacean infestation, the peak was obtained in spring (17.31%) followed by winter (8.70%) then summer (3.33%), and autumn (0%). This result disagrees with Maather Mohamed (2007) who found that the highest infestation was recorded in autumn, while the lowest one was in summer, and also disagrees with Doaa Faisal (2008) who found that the highest infestation was recorded in spring and the lowest was in the winter season. This difference may be due to the geographical distribution of hosts and parasites.

It could be concluded that Scanning electron microscopy was an alternative and additional tool for the accurate identification of *Caligus* species, as it revealed more topical details which not clear by light microscopy.

Ethics

This study was approved by the Ethics Committee of the Suez Canal University. All animal experiments were conducted following the guidelines of the Guide for the Care and Use of Laboratory Animals, Faculty of Veterinary Medicine Science, Suez Canal University, Egypt.

References

1. **Abdel-Gaber,R. et al. (2020)** "Morphological analysis of *Caligus elongatus* von Nordmann, 1832 (Copepoda: Caligidae) from the rosy goatfish *Parupeneus rubescens* (Mullidae)

- " Microscopy Research and Techniue; 83: 1369–1380
2. **Conroy D.A. and Herman L.R. (1981):** Textbook of fish diseases. T.F.H. publ, West Sylvania.
 3. **El-Deen, Noor AE, et al. (2012).** "Field Studies on Caligus disease among cultured Mugil cephalus in brackish water fish farms." LIFE SCIENCE JOURNAL- ACTA ZHENGZHOU UNIVERSITY OVERSEAS EDITION 9.3: 733-737.
 1. **Helna A.K., Kappalli Sudha K., Aneesh P., Anilkumar G. (2018).** *Caligus cybii* (Caligidae, Copepoda) Parasitising the Commercially Exploited Seer Fish, *Scomberomorus commerson*, from the Malabar Coast (India)- Occurrence and Adaptations Turkish Journal of Fisheries and Aquatic Sciences 18: 445-455.
 2. **Kua, B. C., & Faizul, H. (2010).** Scanning electron microscopy of three species of Caligus (Copepoda: Caligidae) parasitized on cultured marine fish at Bukit Tambun, Penang. Malaysian Journal of Microscopy, 6, 9-13.
 3. **Lucky Z. (1977).** Methods for the diagnosis of fish diseases American Publishing Co., Pvt. Ltd., New Delhi, Bombay Calcutta and New York.
 4. **Nelson, J.S. (2006).** Fishes of the World, 4th Edition. John Wiley and Sons, Inc. Hoboken, New Jersey, USA, 601 pp.
 5. **Noga E.J. (1996).** Textbook of "Fish disease" Diagnosis and treatment. Walworth Publishing Co., U. S. A.
 6. **Mahdy O.A. and Abu El Ez M.T.N.(2015).** Additional Morphological Information on Young Female Caligus Kuwaitensis(Copepoda, Siphonostomatoida) from Egyptian Marine Water Fish. Aquaculture Research & Development .6(3)
 7. **Oren, O. H. (Ed.). (1981).** Aquaculture of grey mullets (Vol. 26). CUP Archive.
 8. **Rückert, S., et al. (2008)"**Parasite fauna of seabass (*Lates calcarifer*) under mariculture conditions in Lampung Bay, Indonesia." Journal of Applied Ichthyology 24.3: 321-327.
 9. **Maather Mohamed M.T. (2007).** Studies on the parasitic diseases in some marine fish. Ph .D. Thesis Fac. of Vet. Med. Suez. Canal Univ.
 10. **Doaa Faisal El-S. (2008).** Studies on some parasitic diseases caused by harmful crustaceans in fish . Ph. D. Thesis, Fac. of Vet. Med. (Dept. of Fish Diseases and Management), Suez. Canal. Univ

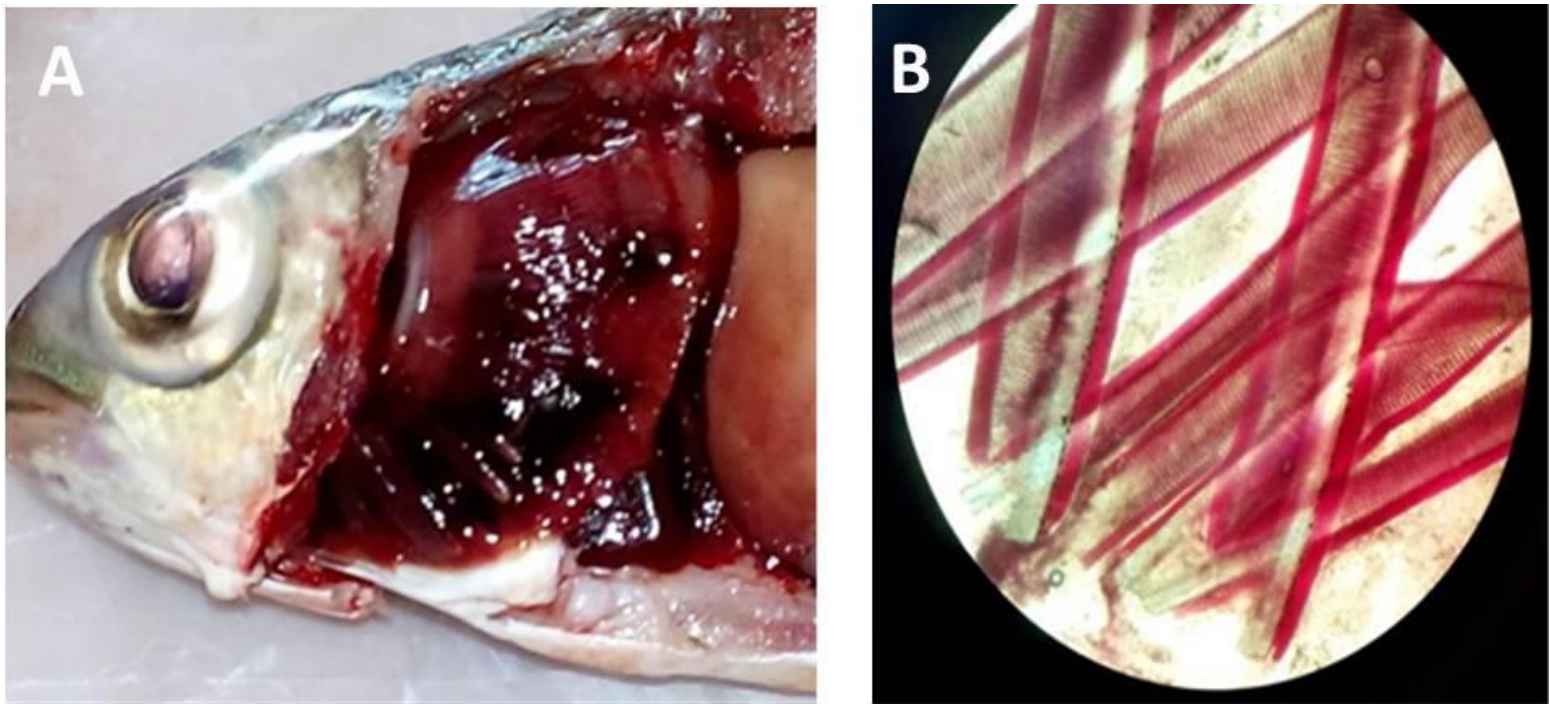


Fig.(1). A: Mosaic appearance in gill of *M. cephalus*. B: Microscopical gill inflammation in *M.cephalus*.


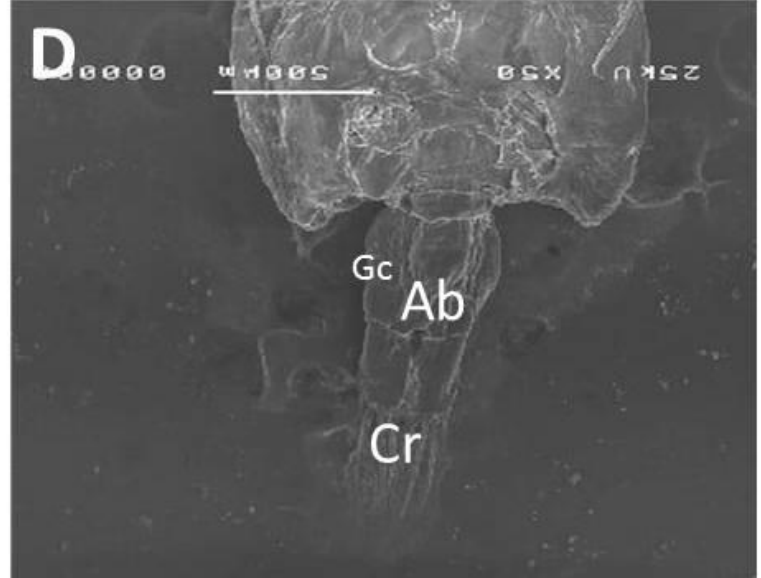
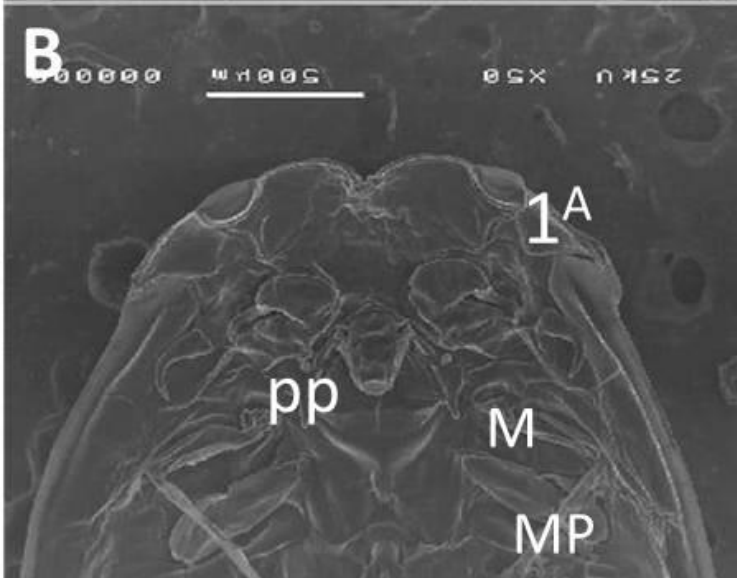
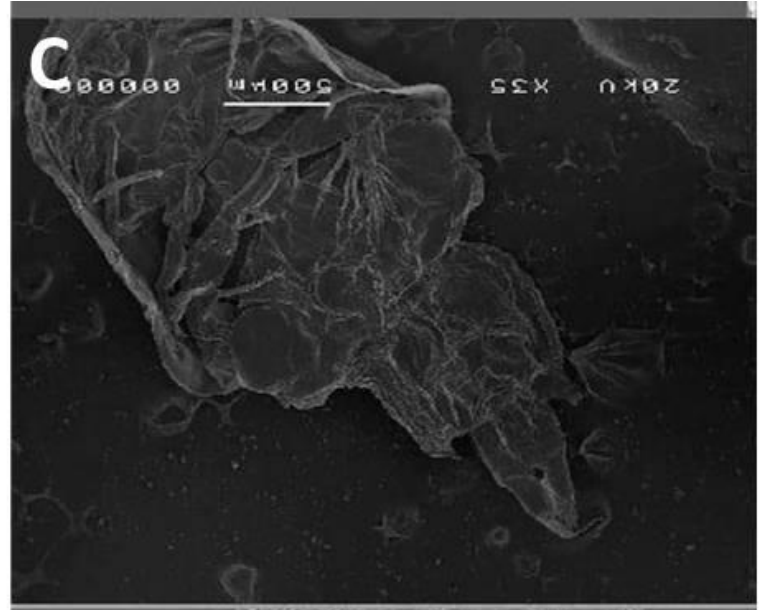
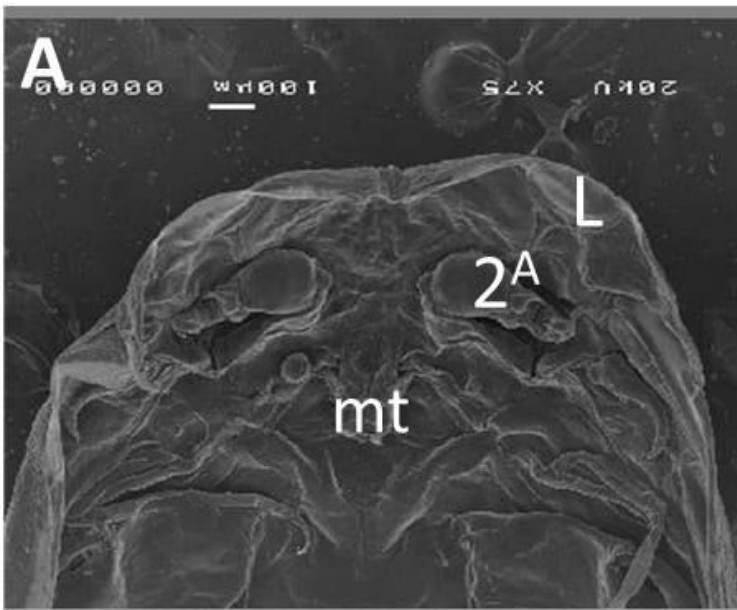


Fig.(2): Light microscope micrographs of Male *Caligus spp.*



Fig(3) Scanning electron micrographs of *Caligus logipedis* (Ventral view).

1^A , first antenna ; MT, mouth tube; 2^A , second antenna; PP, post-antennal process; MP, maxilliped; M, maxilla; Ab,Abdomen ;Cr, caudal rami
Gc, genital complex.

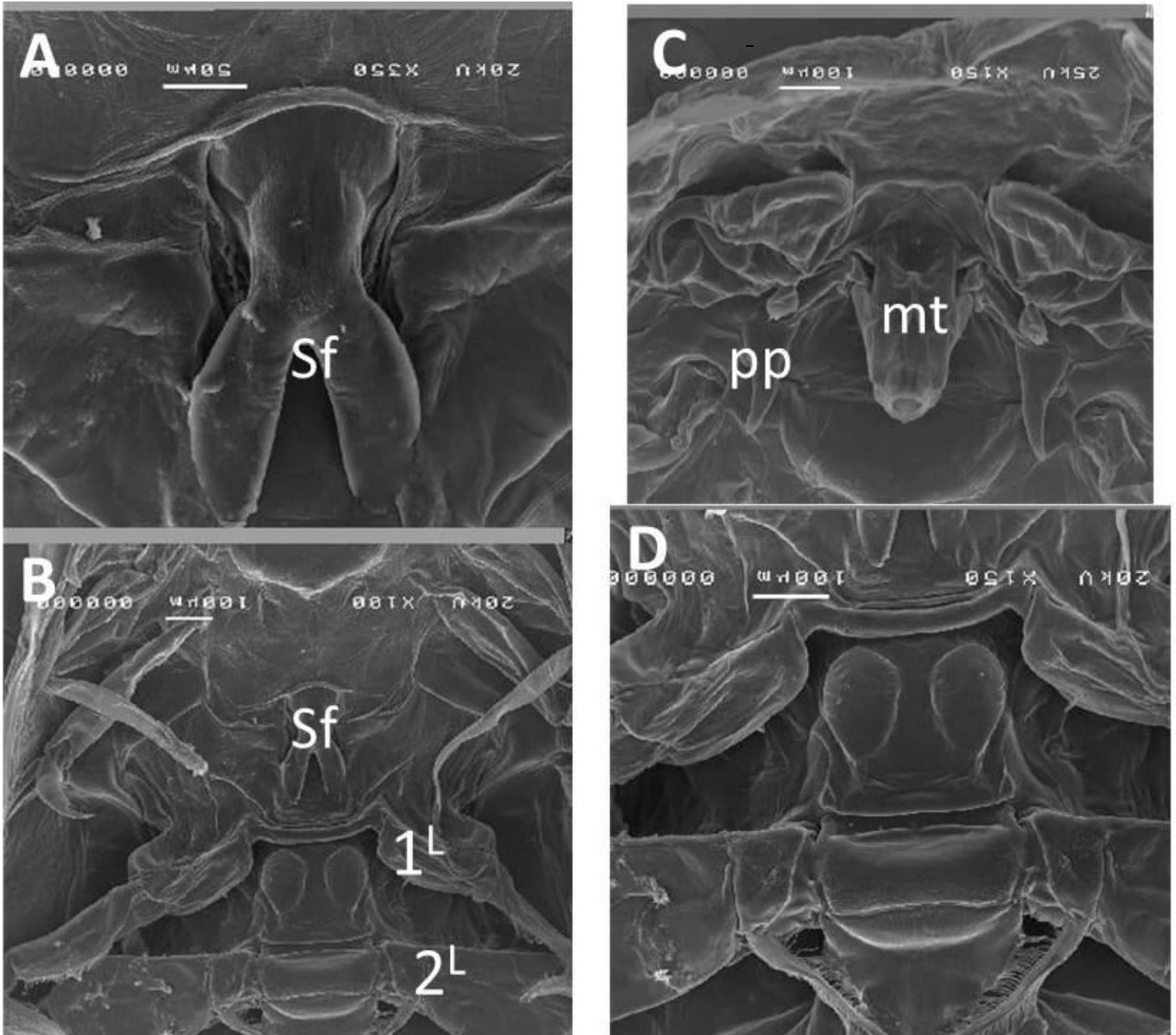


Fig.(4) Scanning electron micrographs of *Caligus logipedis* (Ventral view).
 Sf, Sternal furca; MT, mouth tube ; PP, post-antennal process ; 1^L , first exopod; 2^L , second exopod

Table 1: Prevalence of *Caligus spp.* infestation among the examined fishes:

Fish species	No. of examined fish	No. of infected fish <i>Caligus sp.</i>	%
<i>M. cephalus</i>	63	5	7.94
<i>M. capitus</i>	103	12	11.65
<i>M. seheli</i>	58	0	0
Total	224	17	7.59

Table (2): Seasonal prevalence of *Caligus spp.* infestation among the examined fishes:

Season	Winter			Spring			Summer			Autumn			Total		
	Ex. No	Inf. No	%	Ex. No	Inf. No	%	Ex. No	Inf. No	%	Ex. No	Inf. No	%	Ex. No	Inf. No	%
<i>M. cephalus</i>	27	3	11.11	17	1	5.88	11	1	9.09	8	0	0	63	5	7.94
<i>M. capitus</i>	39	3	7.69	20	8	40	29	1	3.45	15	0	0	103	12	11.65
<i>M. seheli</i>	3	0	0	15	0	0	20	0	0	20	0	0	58	0	0
Total	69	6	8.70	52	9	17.3	60	2	3.33	43	0	0	224	17	7.59

ملخص عربي

الاستعراف التوصيفي باستخدام الميكروسكوب الضوئي والايكتروني على طفيل الكاليجس في العائلة البورية
أ.د./ إسماعيل عبد المنعم محمد عيسى، أ.د./ مني محمود إسماعيل، طب. فاطمة الزهراء رضا أبو المعاطي محمد الحديدي، د./ ايمان محمد
ابوالحسن.

أجريت هذه الدراسة علي 224 سمكة من الأسماك البحرية من ثلاثة أنواع مختلفة تمثلت في أسماك البوري ، الطوبارة و السهيلي والتي تم جمعهم بطريقة عشوائية من المزارع السمكية خلال عام 2015 بمحافظة دمياط بمصر. وقد تم تسجيل معظم العلامات المرضية التي ظهرت علي هذه الأسماك إكلينيكيًا والصفة التشريحية المصاحبة للإصابة والفحوص الطفيلية. أسفر الفحص الإكلينيكي عن وجود بقع نزفية في مناطق الرأس والبطن والذيل وحول الفم والفتحة الشرجية وانتفاخ البطن وتهتكات قشرية في مناطق البطن والذيل مع ظهور قرح. بعض الأسماك أظهرت فقدان الشهية، دكانة لون الجسم، العوم بكسل، السباحة بالقرب من السطح، تآكل الزعانف، فقدان التوازن، العوم بعصبية وجحوظ العين في بعض الحالات مع وجود طفيليات قشرية (كاليجس). أسفر الفحص التشريحي احتقان الخياشيم، بعض الأسماك أظهرت شحوب في الخياشيم وظهور شكل الموزايك في الخياشيم يجمع بين مناطق التهابات وأنزفة دموية ومناطق أنيميا. أعلى نسبة إصابة سجلت في أسماك البوري. تم عزل كاليجس و تم رصد نسب الإصابة الطفيلية لكل نوع من الأسماك